

# Unrecognized B line mimicked pneumothorax on M mode ultrasound

---

Šustić, Alan; Šustić, Marko

Source / Izvornik: **Signa vitae : journal for intensive care and emergency medicine, 2018, 14, 92 - 92**

**Journal article, Published version**

**Rad u časopisu, Objavljena verzija rada (izdavačev PDF)**

<https://doi.org/10.22514/SV141.042018.17>

Permanent link / Trajna poveznica: <https://urn.nsk.hr/urn:nbn:hr:184:438515>

Rights / Prava: [Attribution-NoDerivs 3.0 Unported/Imenovanje-Bez prerada 3.0](#)

Download date / Datum preuzimanja: **2024-12-26**

Repository / Repozitorij:

[Repository of the University of Rijeka, Faculty of Health Studies - FHSRI Repository](#)



# Unrecognized B line mimicked pneumothorax on M mode ultrasound

---

Šustić, Alan; Šustić, Marko

Source / Izvornik: **Signa vitae : journal for intensive care and emergency medicine, 2018, Volume 14, 92 - 92**

Journal article, Published version

Rad u časopisu, Objavljena verzija rada (izdavačev PDF)

<https://doi.org/10.22514/SV141.042018.17>

Permanent link / Trajna poveznica: <https://urn.nsk.hr/urn:nbn:hr:184:513018>

Rights / Prava: [Attribution-NonCommercial-NoDerivatives 4.0 International](#)

Download date / Datum preuzimanja: **2022-07-12**



Repository / Repozitorij:

[Repository of the University of Rijeka, Faculty of Medicine - FMRI Repository](#)



# Unrecognized B line mimicked pneumothorax on M mode ultrasound

MARKO ŠUSTIĆ<sup>1</sup>, ALAN ŠUSTIĆ<sup>1,2</sup>

<sup>1</sup> Faculty of Medicine, University of Rijeka, Croatia

<sup>2</sup> Department of Anesthesiology and ICU, University Hospital Rijeka, Croatia

Corresponding author

Alan Šustić

Department of Anesthesiology and ICU

University Hospital Rijeka

T. Strizica 3, Rijeka, Croatia

Fax: +385 51 21 84 07

E-mail: alan.sustic@uniri.hr

**Key words:** lung ultrasound, B-line, pneumothorax

One of the most significant findings on lung ultrasound (LUS) are comet tail artifacts, also called B-lines or “lung rockets”. The causes of such phenomena are fluid-thickened interlobular septa due to increased extravascular lung water or clinical pulmonary edema. The B-lines are defined as discrete, echogenic, vertical, laser-like signals which arise from the pleural line and extend to the bottom of the screen. (1) However, although originally described as an easily detectable sign, recent reports indicate that other artifacts, such as Z or E lines, may be mistakenly interpreted as B lines (and vice versa). Z lines are short, broad, vertical comet tail artifacts arising from the pleural line, but not reaching the distal edge of the screen. These can be seen in normal lungs, as well as with pneumothorax. E lines are vertical lines, which do not arise from the pleural line, as they originate from subcutaneous collections of gas (subcutaneous emphysema). They are not synchronous with respiratory movements, but they do erase A lines, and may therefore be mistaken for true B lines. (2) Visualization of B lines is considered to rule out pneumothorax (PNX) with a negative predictive value of 100%. On the other hand, visualization of a stratosphere sign (bar code - BC) and a “lung point

sign” (the junction between PNX and an inflating lung) on M mode are established as pathognomonic LUS findings for PNX. Recently, these two findings were described in a patient with chronic obstructive pulmonary disease and without PNX. The authors concluded that these were visualized due to the presence of bullous emphysema, where trapped air in large pulmonary bulla mimicked PNX. (3)

We present the images and a video clip with presentation of BC on M mode, caused by an (unrecognized) B line, mistakenly diagnosed as PNX. In this case, BC was caused by overlapping the unrecognized B line with the cursor (line) in M mode during respiratory movements in a mechanically ventilated patient.

When the B line is not on the M mode cursor, the display shows a normal M mode ultrasound lung finding, termed the “sea shore” sign (figure 1). When the B line crosses the M mode cursor, BC is displayed (figure 2), and alterations of the “sea shore sign” and BC sign can easily be mistaken for a “lung point sign” (video clip).

These images point out the importance of clear identification and distinction of B lines from (in some cases) similar Z and E lines. Both 2-D and M-modes of LUS should be used and interpreted for accurate diagnostic value.

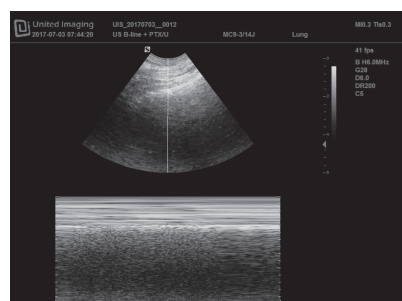


Figure 1. M mode image: “sea shore sign”.

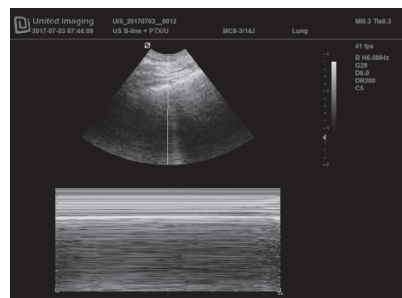


Figure 2. M mode image in the same patient: “bar code sign”.

## REFERENCES

1. Dietrich CF, Mathis G, Blaivas M, Volpicelli G, Siebel A, Atkinson NSS, et al. Lung B-line artefacts and their use. *J Thorac Dis* 2016;8:1356-65.
2. Neto FJM, Rahal A, Vieira FAC, da Silva PSD, de Gusmao Funari MB. Advances in lung ultrasound. *Einstein (Sao Paulo)* 2016;14:443-8.
3. Aziz SG, Patel BB, Susanti R, Rubio ER. The lung point sign, not pathognomonic of a pneumothorax. *Ultrasound Quarterly* 2016;32:277-9.